解剖列車原則及肌筋膜放鬆術原理
(Basic Principle and Rules of Anatomy Trains Myofascial Meridians)

張曉昀
國立體育大學運動保健學系
前中山醫學大學物理治療學系系主任
yun1130@ntsu.edu.tw

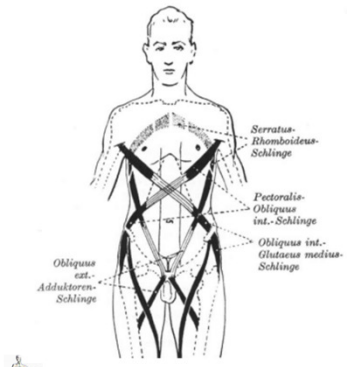

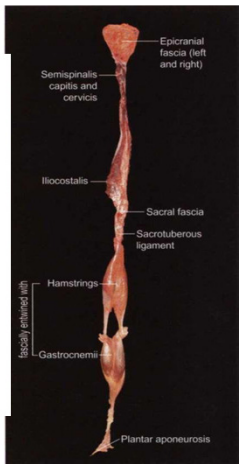

12 myofascial meridians

- Superficial back line 淺層背部路徑
- Superficial front line淺層腹部路徑
- Lateral line (2 side)外側路徑
- Spiral line旋轉路徑
- Arm line (4 line)手臂路徑
- Functional line (frontal and back)功能性路徑
- Deep front line 深層腹部路徑: 顱薦椎療法(CST), 臟器鬆動術(VM)

Superficial back line (淺層背部路徑)

- Postural function(在姿勢上的功能)
  - Support the body in full upright extension(支持身體直立)
  - higher proportion of slow-twitch, endurance muscle fibers in the muscular portions of this myofascial band(具備較高比例之慢肌與耐力型肌纖維)

Table 3.1 Superficial Back Line: myofascial 'tracks' and bony 'stations' (Fig. 3.2)

Bony stations		Myofascial tracks
Frontal bone, supraorbital ridge	13	
	12	Galea aponeurotica/epicranial fascia
Occipital ridge	11	
	10	Sacrolumbar fascia/erector spinae
Sacrum	9	
	8	Sacrotuberous ligament
Ischial tuberosity	7	
	6	Hamstrings
Condyles of femur	5	
	4	Gastrocnemius/Achilles tendon
Calcaneus	3	
	2	Plantar fascia and short toe flexors
Plantar surface of toe phalanges	1	

表 3.1 淺背線：肌筋膜「軌道」和骨骼性「車站」(圖 3.2)

骨骼性車站		肌筋膜軌跡
額骨，眶上嵴	13	
	12	帽狀腱膜／顱頂筋膜
枕嵴	11	
	10	腰薦部筋膜／豎脊肌
薦骨	9	
	8	薦粗隆韌帶
坐骨粗隆	7	
	6	腿旁腱肌
股骨髁	5	
	4	腓腸肌／亞基里斯跟腱
跟骨	3	
	2	足底筋膜和屈趾短肌
趾骨蹠面	1	

Forward bend test(前彎測試)

Fig. 3.10 A forward bend with the knees straight links and challenges all the tracks and stations of the Superficial Back Line. Work in one area, as in this move for the plantar fascia, can affect motion and length anywhere and everywhere along the line. After work on the right plantar surface, the right arm hangs lower.

Soleus and gastrocnemius technique
(比目魚肌 & 腓腸肌技術)

2020/6/13

http://www.youtube.com/watch?v=boBqqNIJ5T0

Hamstring technique
(腿後肌技術)

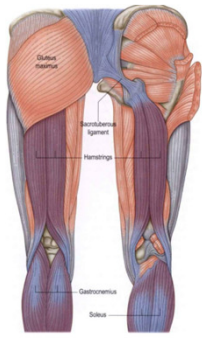

Fig. 3.21 A superficial view (left) shows the hamstrings disappearing under the gluteus maximus, but despite the gluteus being a superficial muscle on the back, it is not part of the SBL. It is disqualified by involving both a change in direction, and a change of level. Remove the gluteus (which will show up later as part of other lines) to see the clear connection from the hamstrings to the sacrotuberous ligament.

2020/6/13

http://www.youtube.com/watch?v=BJBu9I_Hzu0&list=UUQQKQa8TRfgZC901e3iO8nw

Erector spinae fascia(豎脊肌技術)

Fig. 3.25 Working the erector spinae and associated fascia in eccentric contraction from a bench is a very effective way of creating change in the myofascial function around the spine.

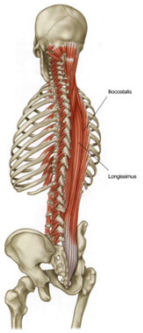

Fig. 3.23 The erector spinae form the next track of the SBL. The muscles run from the sacrum to the occiput; the fascia runs from the sacrotuberous ligament to the scalp fascia. On the left are some of the underlying 'locals' of the transversospinalis - intertransversarii, rotators, and levatores costarum.

2020/6/13

Suboccipitals and Scalp technique
(枕骨下及頭皮技術)

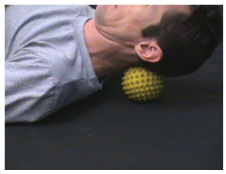

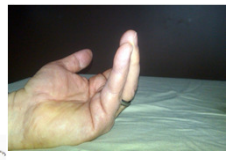

2020/6/13

Superficial front line
(淺層腹部路徑)

- Postural function(在姿勢上的功能)
  1. Balance SBL (SFL+DFL)(平衡淺層背部路徑)
  2. Tensile support the forward skeleton(給予身體前側骨骼一個張力支撐)
  3. Postural extension of knee(維持膝蓋伸直)
  4. Defend sensitive ventral part (保護較敏感的腹側)

2020/6/13

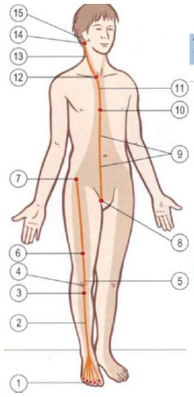

Table 4.1 Superficial Front Line: myofascial 'tracks' and bony 'stations' (Fig. 4.2)

Bony stations		Myofascial tracks
	15	Scalp fascia
Mastoid process	14	
	13	Sternocleidomastoid
Sternal manubrium	12	
	11	Sternalis/sternochondral fasci
5th rib	10	
	9	Rectus abdominis
Pubic tubercle	8	
Anterior inferior iliac spine	7	
	6	Rectus femoris/quadriceps
Patella	5	
	4	Subpatellar tendon
Tibial tuberosity	3	
	2	Short and long toe extensors, tibialis anterior, anterior crural compartment
Dorsal surface of toe phalanges	1	

Fig. 4.2 Superficial Front Line tracks and stations. The shaded area shows the area of superficial fascial influence.

表 4.1 淺前線：肌筋膜「軌道」與骨骼性「車站」(圖 4.2)

骨骼性車站		肌筋膜軌道
	15	頭皮筋膜
乳突	14	
	13	胸鎖乳突肌
胸骨柄	12	
	11	胸骨肌／胸軟骨筋膜
第五肋骨	10	
	9	腹直肌
恥骨結節	8	
前下髂棘	7	
	6	股直肌／股四頭肌
髕骨	5	
	4	髕骨下肌腱
脛骨粗隆	3	
	2	伸趾長、短肌、脛前肌、小腿前側隔間

2020/6/13

測試

- 股四頭肌

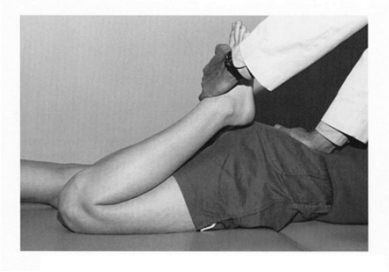

Extensor retinaculum technique
伸趾肌群支持帶

Tibialis Anterior & Peroneus technique
脛前肌 & 腓骨肌群技術

Quadriceps technique
(股四頭肌技術)

http://www.youtube.com/watch?v=djjTid58-Ow

Lateral line(側面路徑)

- Postural function(在姿勢上的功能)
  - To balance frontal and back, and bilateral to balance left and right(平衡前後方向以及雙側平衡左右方向)
  - The LL fixes the trunk and legs in a coordinated manner to prevent buck-ling of the structure during any activity with the arms.

(協調軀幹和下肢活動，避免在任何使用上肢所進行的活動中發生結構鬆弛的情形)

表 5.1 側向線：肌筋膜「軌道」和骨骼性「車站」(圖 5.2)

骨骼性車站		肌筋膜軌道
枕骨線／乳突	19	
	17,18	頭夾肌／胸鎖乳突肌
第一和第二肋骨	16	
	14,15	外和內肋間肌
肋骨	13	
	11,12	外側腹斜肌
髂嵴，前上髂棘 (ASIS)，後上髂棘 (PSIS)	9,10	
	8	臀大肌
	7	闊筋膜張肌
	6	髂脛束／外展肌
外側脛骨髁	5	
	4	腓骨頭前韌帶
腓骨頭	3	
	2	腓骨肌，外側小腿隔間
第一和第五蹠骨基部	1	

Table 5.1 Lateral Line: myofascial "tracks" and bony "stations" (Fig. 5.2)

Bony stations		Myofascial tracks
Occipital ridge/mastoid process	19	
	17, 18	Splenius capitis/ sternocleidomastoid
1st and 2nd ribs	16	
	14, 15	External and internal intercostals
Ribs	13	
	11, 12	Lateral abdominal obliques
Iliac crest, ASIS, PSIS	9, 10	
	8	Gluteus maximus
	7	Tensor fasciae latae
	6	Iliotibial tract/abductor muscles
Lateral tibial condyle	5	
	4	Anterior ligament of head of fibula
Fibular head	3	
	2	Peroneal muscles, lateral crural compartment
1 st and 5th metatarsal bases	1	

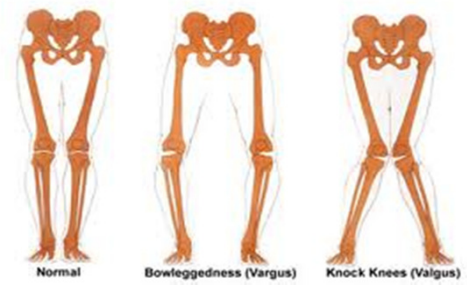

2020/6/13

測試

- 腰部側彎

2020/6/13

ITB technique
髂脛束技術

2020/6/13

Iliac crest and waist(髂脊 & 腰)

2020/6/13

Spiral line (SPL)(旋轉路徑)

- Postural function(姿勢上的功能)
  - Maintain balance across all planes(平衡所有的平面)
  - Connect the foot arches with pelvic angle, and help to determine efficient knee-tracking in walking(連接足弓與骨盆角度，並幫助判斷行走時膝蓋軌道的效益)
  - Maintain twists, rotations, and lateral shift in the body(維持身體扭轉、旋轉和側向位移等過程)
  - Participates in the others meridians (參與其他路徑)

2020/6/13

表 6.1 旋線：肌筋膜「軌道」和骨骼性「車站」(圖 6.2)

骨骼性車站		肌筋膜軌道
枕骨嵴／乳突 寰椎／橫椎 TPs	1	
	2	頭和頸夾肌
頸椎下半部／胸椎上半部 SPs	3	
	4	大小菱形肌
肩胛骨內緣	5	
	6	前鋸肌
外側肋骨	7	
	8	腹外斜肌
	9	腹肌鞘膜，白線
	10	腹內斜肌
髂嵴／前上髂棘 (ASIS)	11	
	12	闊筋膜張肌，髂脛束
外側脛骨髁	13	
	14	脛前肌
第一跖骨基部	15	
	16	腓長肌
腓骨頭	17	
	18	股二頭肌
坐骨粗隆	19	
	20	薦結節韌帶
薦骨	21	
	22	薦腰筋膜，豎脊肌
枕骨嵴	23	

Table 6.1 Spiral Line: myofascial 'tracks' and bony 'stations' (Fig. 6.2)

Bony stations		Myofascial tracks
Occipital ridge/mastoid process atlas/axis TPs	1	
	2	Splenius capitis and cervicis
Lower cervical/upper thoracic SPs	3	
	4	Rhomboids major and minor
Medial border of scapula	5	
	6	Serratus anterior
Lateral ribs	7	
	8	External oblique
	9	Abdominal aponeurosis, linea alba
	10	Internal oblique
Iliac crest/ASIS	11	
	12	Tensor fasciae latae, iliotibial tract
Lateral tibial condyle	13	
	14	Tibialis anterior
1st metatarsal base	15	
	16	Peroneus longus
Fibular head	17	
	18	Biceps femoris
Ischial tuberosity	19	
	20	Sacrotuberous ligament
Sacrum	21	
	22	Sacrolumbar fascia, erector spinae
Occipital ridge	23	

2020/6/13

Upper Spiral Line(上旋路徑)

- Splenius capitis & cervicis(頭夾肌和頸部肌肉)
- Cervical spinous process(頸椎棘突)
- Rhomboids(菱形肌)
- Medial border of scapula(肩胛骨內側緣)
- Serratus anterior(前鋸肌)
- External oblique(腹外斜肌)
- Rectus abdominis and fascia(腹直肌筋膜)
- Internal oblique(腹內斜肌)
- ASIS and iliac crest (髂骨前上脊和髂嵴)

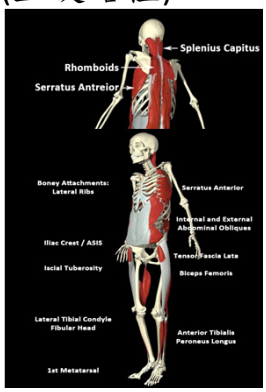

2020/6/13

Dynamic knee valgus
動態性膝關節外翻

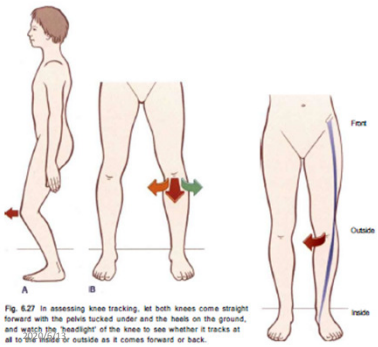

Fig. 6.27 In assessing knee tracking, let both knees come straight forward with the pelvis tucked under and the heels on the ground, and watch the 'headlight' of the knee to see whether it tracks at all to the inside or outside as it comes forward or back.

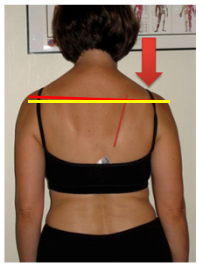

Fig. 6.28 Because the Spiral Line passes from the front of the hip to the outside of the knee to the inside of the ankle, tightening this line can tend to induce medial rotation at the knee.

Serratus anterior technique
前鋸肌技術

- Video

2020/6/13

Arm Lines

- **4 arm lines**
  - Superficial Front Arm Line
    淺層前側手臂路線
  - Deep Front Arm Line
    深層前側手臂路線
  - Superficial Back Arm Line
    淺層背側手臂路線
  - Deep Back Arm Line
    深層背側手臂路線

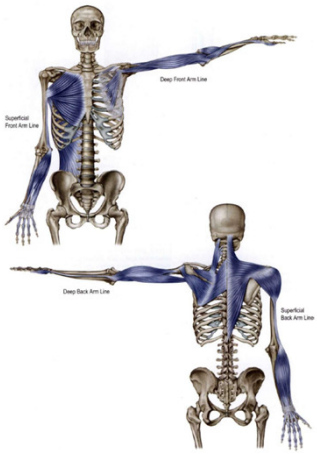

2020/6/13

表 7.1 上臂線：筋膜「軌道」與骨骼性「車站」(圖 7.2)

骨骼性車站		肌筋膜軌道
A. 深前臂線		
第三、第四與第五肋骨	1	
	2	胸小肌、鎖胸筋膜
喙突	3	
	4	肱二頭肌
橈骨粗隆	5	
	6	橈骨骨膜、前緣
橈骨莖突	7	
	8	橈側副韌帶、大魚際肌群
舟狀骨、大多角骨	9	
大拇指外側	10	
B. 淺前臂線		
鎖骨內側三分之一、肋軟骨、胸腰筋膜、髂嵴	1	
	2	胸大肌、闊背肌
內側肱骨線	3	
	4	內側肌間隔
內側肱骨上髁	5	
	6	屈肌群
	7	腕隧道
手指的掌側面	8	

2020/6/13

Table 7.1 Arm Lines: myofascial 'tracks' and bony 'stations' (Fig. 7.2)

Bony stations		Myofascial tracks
A. Deep Front Arm Line		
3rd, 4th and 5th ribs	1	
	2	Pectoralis minor, clavipectoral fascia
Coracoid process	3	
	4	Biceps brachii
Radial tuberosity	5	
	6	Radial periosteum, anterior border
Styloid process of radius	7	
	8	Radial collateral ligaments, thenar muscles
Scaphoid, trapezium	9	
Outside of thumb	10	
B. Superficial Front Arm Line		
Medial third of clavicle, costal cartilages, thoracolumbar fascia, iliac crest	1	
	2	Pectoralis major, latissimus dorsi
Medial humeral line	3	
	4	Medial intermuscular septum
Medial humeral epicondyle,	5	
	6	Flexor group
	7	Carpal tunnel
Palmar surface of fingers	8	

C. 深背臂線		
頸椎下部和胸椎上部的棘突、第一到第四節頸椎橫突 (C1-4 TPs)	1	
	2	菱形肌和提肩胛肌
肩胛骨內緣	3	
	4	肩旋轉袖肌群
肱骨頭	5	
	6	肱三頭肌
尺骨鷹嘴	7	
	8	尺骨骨膜
尺骨莖突	9	
	10	尺側副韌帶
三角骨、鉤骨	11	
	12	小魚際肌群
小指外側	13	
D. 淺背臂線		
枕骨嵴、項韌帶、胸椎棘突	1, 2, 3	
	4	斜方肌
肩胛棘、肩峰、鎖骨外側三分之一	5	
	6	三角肌
肱骨的三角肌粗隆	7	
	8	外側肌間隔
外側肱骨上髁	9	
	10	伸肌群
手指的背側面	11	

2020/6/13

C. Deep Back Arm Line		
Spinous process of lower cervicals and upper thoracic, C1-4 TPs	1	
	2	Rhomboids and levator scapulae
Medial border of scapula	3	
	4	Rotator cuff muscles
Head of humerus	5	
	6	Triceps brachii
Olecranon of ulna	7	
	8	Ulnar periosteum
Styloid process of ulna	9	
	10	Ulnar collateral ligaments
Triquetrum, hamate	11	
	12	Hypothenar muscles
Outside of little finger	13	
D. Superficial Back Arm Line		
Occipital ridge, nuchal ligament, thoracic spinous processes	1, 2, 3	
	4	Trapezius
Spine of scapula, acromion, lateral third of clavicle	5	
	6	Deltoid
Deltoid tubercle of humerus	7	
	8	Lateral intermuscular septum
Lateral epicondyle of humerus	9	
	10	Extensor group
Dorsal surface of fingers	11	

檢測

- 胸小肌

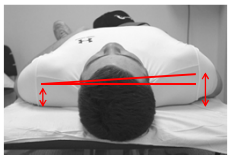

2020/6/13

Technique: Pectoralis minor
胸小肌技術

Fig. 7.8 The hand approaches the pectoralis minor from the axilla, under the pectoralis major, with the fingers heading in the direction of the sternoclavicular joint.

2020/6/13

Pectoralis minor stretch
胸小肌伸展

Fig. 7.9 Dropping the shoulder blades down the back and bringing them together while keeping the lumbars back will stretch and open the pectoralis minor and surrounding tissues.

2020/6/13

SFAL / DFAL stretch
手臂淺層/深層前側路徑伸展

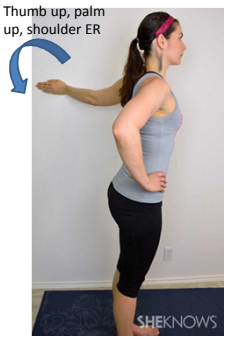

2020/6/13

Deltoid technique
三角肌技術

https://www.youtube.com/watch?v=aUX4k5WmI74

2020/6/13

Infraspinatus Technique
脊下肌技術

https://www.youtube.com/watch?v=Uw65cvVbS9I

2020/6/13

Functional Line
功能性路線

- They come into play during athletic or where one appendicular complex is stabilized, counterbalanced, or powered by its contralateral complement

- Example: Javelin throw or a baseball pitch

2020/6/13

Functional Line

- Postural function
  在姿勢上的功能

1. Extensions of the Arm Line手臂路線的延伸
2. Bring shoulder closer to its opposite hip if they distort whole posture
   將肩膀帶靠近對側髖部
3. Strong postural stabilization, or counterbalance for the work of the lower limb
   具有很強的穩定姿勢功能，或讓下肢動作時做抗衡

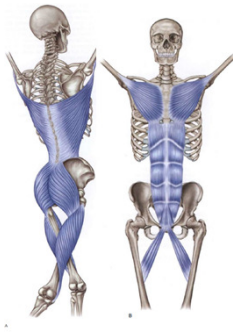

2020/6/13

Functional Line

- Movement function動作功能

1. Give extra power給予額外爆發力
2. lengthening their lever arm through linking to giving additional momentum
   延長手臂槓桿
3. Work in helical patterns螺旋性動作
4. Appendicular supplements to the Spiral Line附加支持旋線

2020/6/13

Functional Line

- Back functional line

Bony stations		Myofascial tracks
Back Functional Line		
Shaft of humerus	1	
	2	Latissimus dorsi
	3	Lumbodorsal fascia
	4	Sacral fascia
Sacrum	5	
	6	Gluteus maximus
Shaft of femur	7	
	8	Vastus lateralis
Patella	9	
	10	Subpatellar tendon
Tuberosity of tibia	11	

表 8.1　功能線：肌筋膜「軌道」與骨骼性「車站」(圖 8.2)

骨骼性車站		肌筋膜軌道
背功能線		
肱骨骨幹	1	
	2	闊背肌
	3	腰背筋膜
	4	薦筋膜
薦椎	5	
	6	臀大肌
股骨骨幹	7	
	8	股外側肌
髕骨	9	
	10	髕骨下肌腱
脛骨粗隆	11	

2020/6/13

Functional Line

- Frontal functional line

Bony stations		Myofascial tracks
Front Functional Line		
Shaft of humerus	1	
	2	Lower edge of pectoralis major
5th rib and 6th rib cartilage	3	
	4	Lateral sheath of rectus abdominis
Pubic tubercle and symphysis	5	
	6	Adductor longus
Linea aspera of femur	7	

前功能線		
肱骨骨幹	1	
	2	胸大肌下緣
第五和第六肋間軟骨	3	
	4	腹直肌外鞘
恥骨結節和聯合	5	
	6	外展長肌
股骨粗線	7	

2020/6/13

Tennis forehand/backhand

Fig. 8.4 The Front Functional Line in a tennis serve. The stronger and more vertical the serve, the more the Superficial Front Line will also participate in driving the ball.

2020/6/13

Latissimus dorsi Techniques
擴背肌技術

- video

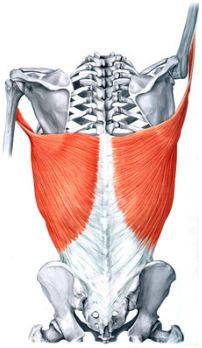

https://www.youtube.com/watch?v=LuB-qCgJnUg

自主肌筋膜放鬆術及操作
(Self-myofascial release technique and practice)

前言

- 自我肌筋膜放鬆近年來受到歡迎，特別在體適能訓練員與臨床從事人員有較好的工具來放鬆肌肉壓力
- 自我肌筋膜放鬆效果
  1) 矯正肌肉不平衡
  2) 改善關節活動度
  3) 緩解肌肉痠痛
  4) 改善神經肌肉效率
  5) 減少關節壓力

累積性傷害的因果循環
(Cumulative injury cycle)

常用的器材

技巧與方式

- **頻率與強度**
  - 必須注意給予的質量必須要符合當下接受放鬆的組織強度
  - 每一個部位使用約1-2分鐘
  - 高爾肌腱器反映：7-10秒
  - 感覺疼痛或酸痛，直到感覺消失
  - 重複次數：1-3次

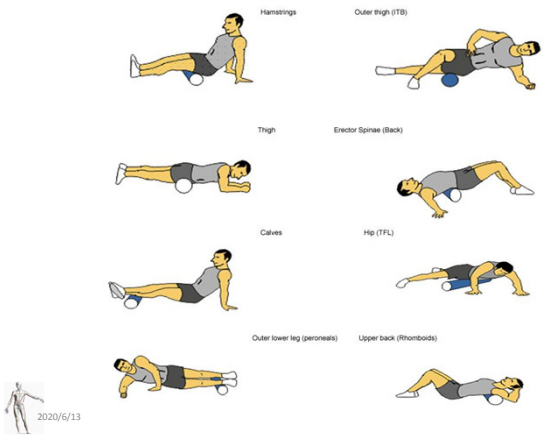
Hamstrings
Outer thigh (ITB)
Thigh
Erector Spinae (Back)
Calves
Hip (TFL)
Outer lower leg (peroneals)
Upper back (Rhomboids)
2020/6/13